

Radiographic Evaluation of Two Early Classic Elites from Copan, Honduras

K. C. NYSTROM,^{a*} J. E. BUIKSTRA^a AND E. M. BRAUNSTEIN^b

^a *Department of Anthropology, University of New Mexico, Albuquerque, NM 87131, USA*

^b *Department of Radiology, Mayo Clinic, Scottsdale, AZ 85259 and Department of Anthropology, Northern Arizona University, Flagstaff, AZ 86011, USA*

ABSTRACT The paper describes the results of a radiographic evaluation of two elite individuals from the Early Classic period of Copan, Honduras; K'inich Yax K'uk' Mo', founder of the Early Classic Dynasty at Copan; and the principal individual recovered from the Motmot tomb. There were two primary goals: (1) the description of previously undocumented pathological processes; and (2) the evaluation of individual-specific forms of pathology and activity-related changes such as disuse atrophy. Despite suffering from a number of blunt force insults, K'inich Yax K'uk' Mo's cortical and trabecular bone thickness appears normal, indicating that the skeletal elements did not suffer from disuse atrophy concomitant following injury. Additionally, we examined the Motmot individual for: (1) evidence of bone thinning, either associated with reduced activity levels or pathology; (2) evidence of a parry fracture to her right forearm; and (3) the evaluation of a possible fracture to the right humerus near the surgical neck. In sum, despite her gracile appearance, we concluded that Motmot did not suffer from cortical bone thinning due to disease process or reduced activity levels, and that the right forearm parry fracture was the only sign of blunt force trauma. Copyright © 2005 John Wiley & Sons, Ltd.

Key words: Palaeoradiography; Copan; blunt force trauma; Polaroid film

Introduction

Physical anthropologists working with ancient human remains from the Americas are usually presented with skeletons that have no identity beyond an archaeologically derived cultural affiliation. The ancient Maya are an exception, however, as hieroglyphic texts and iconography document history and therefore there is the possibility of connecting skeletal remains to historical figures. The research project described involves such an instance. It informs us on the reconstruction of Early Classic Maya lifeways, and includes a detailed radiographic analysis of blunt force trauma. Radiographic technology was

implemented to add detail to interpretations derived from the gross evaluation of pathology. The project goals included: (1) the documenting of pathological processes that may not have an externally visible manifestation; and (2) the assessment of changes in bone structure concomitant with trauma which may be evidence of individual-specific forms of pathology and activity-related changes such as disuse atrophy. Observations were made on two elite individuals from the Early Classic period of Copan (ca. AD 400–600): K'inich Yax K'uk' Mo', founder of the Early Classic Dynasty at Copan; and the principal individual recovered from the Motmot tomb.

The site of Copan is located near the southeastern limit of the Maya region in modern day Honduras (Figure 1). The chronology of Copan can be divided into three periods. The Proto-classic, or Predynastic period, is characterised by

* Correspondence to: Department of Anthropology, University of New Mexico, Albuquerque, NM 87131, USA.
e-mail: knystrom@unm.edu

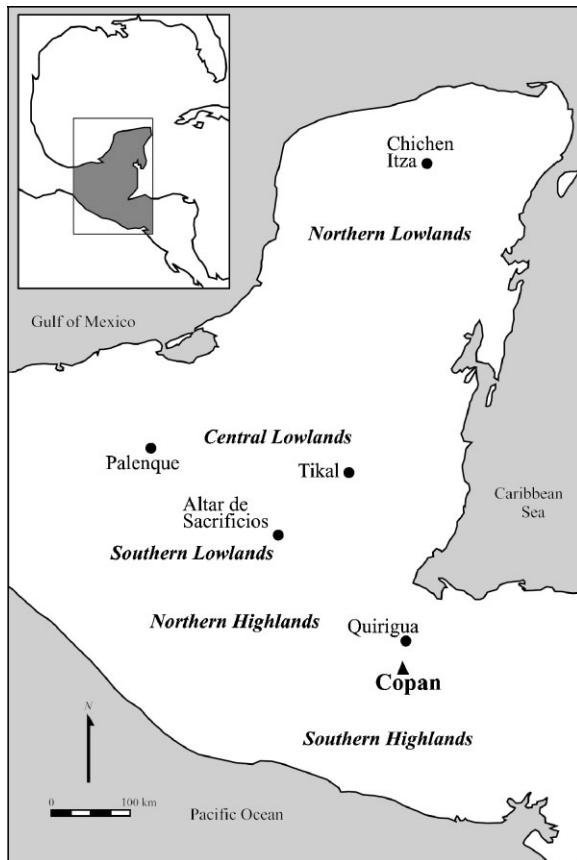


Figure 1. Copan and its regional context.

the Bijac ceramic phase and dates to ca. AD 100–400. The Early Classic period of Copan is defined by the Acbi ceramic phase (ca. AD 400–600) and included the reigns of the first ten rulers of Copan. The Late Classic period at Copan is defined by the Coner ceramic phase (ca. AD 600–850). The skeletal remains of the two elite individuals analysed in the current study date to the Early Classic period.

The urban centre of Copan is situated within the largest of a series of alluvial pockets carved by the Copan River. The Principal Group represents the remains of the Classic Maya polity capital and consists of plazas to the north and a series of superimposed structures to the south. A ballcourt and Structure 10L-26 (Temple of the Hieroglyphic Stairway) demarcate these north and south components. The elevated Acropolis is divided into two enclosed courts by Structure 10L-25 and Structure 10L-16. The latter is the highest point in the Principal Group and repre-

sents a pivotal period in the history of the Acropolis (Canuto *et al.*, 2004).

The Hunal Tomb (Burial 95-2) is located in the earliest levels of the Acropolis (Structure 10L-16). Stratigraphic, ceramic and epigraphic evidence all date the Hunal Tomb to ca. AD 400–450 (Bell *et al.*, 2004). The tomb and its remains were disturbed by human activity, seismic events and water infiltration, yet the remains appear to have rested initially upon a fine reed mat and were accompanied by a number of shell and jade ornaments, bone implements and ceramics (Bell *et al.*, 2004). The remains have been attributed to K'inich Yax K'uk' Mo', founder of the Early Classic Dynasty of Copan. K'inich Yax K'uk' Mo' is said to have arrived and consolidated political power within the Copan Valley in AD 426 (Schele, 1986; Stuart and Schele, 1986; Sharer, 1997; Sharer *et al.*, 1999).

Excavations below Structure 10L-26 (Fash *et al.*, 2004) revealed other Early Classic period burials, including the Motmot Tomb. The principal interment in the Motmot tomb (Burial 37-8) was that of a seated young female. The tomb was capped with a circular marker inscribed with iconography that suggests it was constructed during the reign of Ruler 2, the son and successor of K'inich Yax K'uk' Mo' (Fash *et al.*, 2004). The tomb was reopened and there is evidence for the use of fire and the inclusion of at least two more skulls (Fash *et al.*, 2004). Based upon the material found in association with the remains, the young woman may have been a day-keeper, an individual associated with divination and curing (Fash *et al.*, 2004).

In addition to the goals stated above, there were three goals that specifically dealt with our evaluation of the Motmot individual: (1) identification of evidence for bone thinning, either associated with reduced activity levels or pathology; (2) an evaluation of a parry fracture of her right forearm; and (3) evaluation of a minor asymmetry of the proximal humeri as possible evidence for a fracture of the right humerus at the surgical neck.

Previous research

There are few reports of blunt force trauma among the Maya, especially in reference to the

elites. Saul & Saul (1997) reported blunt force trauma rates from the PreClassic site of Cuello. Most fractures were observed on skeletal remains recovered from the Chicanel phase of the site (400 BC–AD 25), which consisted of two different contexts; the first consisted of two mass burials of only male individuals, while the second context was residential. Examples of healed trauma in the former sample includes malaligned 'parry' fractures of the left radius and ulna, Colles fractures of the distal left radius, a fractured foot phalanx, and finally a fractured left capitate and lunate (Saul & Saul, 1997). Based upon the higher frequency of fractures in the Chicanel males, Saul & Saul (1997) suggested that these individuals were at an unusually high risk of such trauma, perhaps through combat or sports, although whether this was by virtue of their social status or sex is unclear (Saul & Saul, 1997: 43).

Armstrong (1989) examined 275 adult Colonial burials from Tipu, and found relatively low rates of trauma, with three examples of parry fractures. While there was some suggestion that some of the trauma from the Tipu sample was due to violence, in general trauma frequency increased gradually with age, and Armstrong concluded that most of the fractures appear to have been the result of accidents. These burials, however, do not seem to represent an elite section of the population (Cohen *et al.*, 1997).

Whittington (1989: 363–5) reported observing only one example of a parry fracture from his analysis of Classic period (AD 400–950) low-status individuals from Copan. Furthermore, he stated that only one other parry fracture has been reported for ancient Maya materials.

In a recent study, Buikstra *et al.* (2004) documented remarkable evidence of blunt force trauma among elite individuals from an Early Classic period context at Copan. Here, we extend that investigation, which was limited to gross observations, to include radiographic assessment of pathology for K'inich Yax K'uk' Mo' and the principal interment within the Motmot tomb.

Materials and methods: radiography

Radiographs were taken using a Soyee Products Inc. portable veterinary x-ray unit. Safety proce-

dures, including protective lead aprons and researcher isolation, were followed to reduce radiation exposure. Given the logistics of the research locales, including both a laboratory setting (Motmot interment 37-8) and tunnels set within the Copan Acropolis (K'inich Yax K'uk' Mo'), the use of conventional radiographic film was infeasible. Instead of conventional film, 8" × 10" sheets of 800 ISO Polapan 803 Polaroid film, a black-and-white photographic film, were used. Polaroid film has advantages over conventional radiographic film when dealing with field conditions (Conlogue & Nelson, 1999), including instant assessment of exposure and positioning, and sharp, positive images (Figure 2a and b). Its disadvantages, however, include the limited size of the film, which at times necessitated multiple exposures to capture the full length of long bones. Despite these caveats the use of Polaroid film was chosen. Exposures were generally set at 80 kV/15 mA and the focal film distance was approximately 100 cm (40 inches) above the level of the film. Power fluctuations within both the laboratory and tunnels made it difficult to maintain these levels, therefore exposure times varied from under 10 seconds for thin bones such as ribs and scapulae, to 35 seconds for cranial and long bones. As such, care must also be taken when assessing differences in radiodensity between elements that were exposed on different films. This concern, however, will only affect the interpretation of a single figure in this research. All other figures consist of single exposures. Another obstacle encountered during the research was cinnabar that had been applied to the bones prior to deposition. Cinnabar, a naturally occurring form of mercury, is radiodense and at times was so ubiquitous on the skeletal elements that the resulting radiographs had no diagnostic power. One of the authors, EMB, a radiologist from the Mayo Clinic, while not involved in the actual exposure of the films, reviewed the radiographs.

Radiographic assessment of pathology

K'inich Yax K'uk' Mo' interment

Standard osteological methods concluded that the Hunal tomb contained a single set of partially

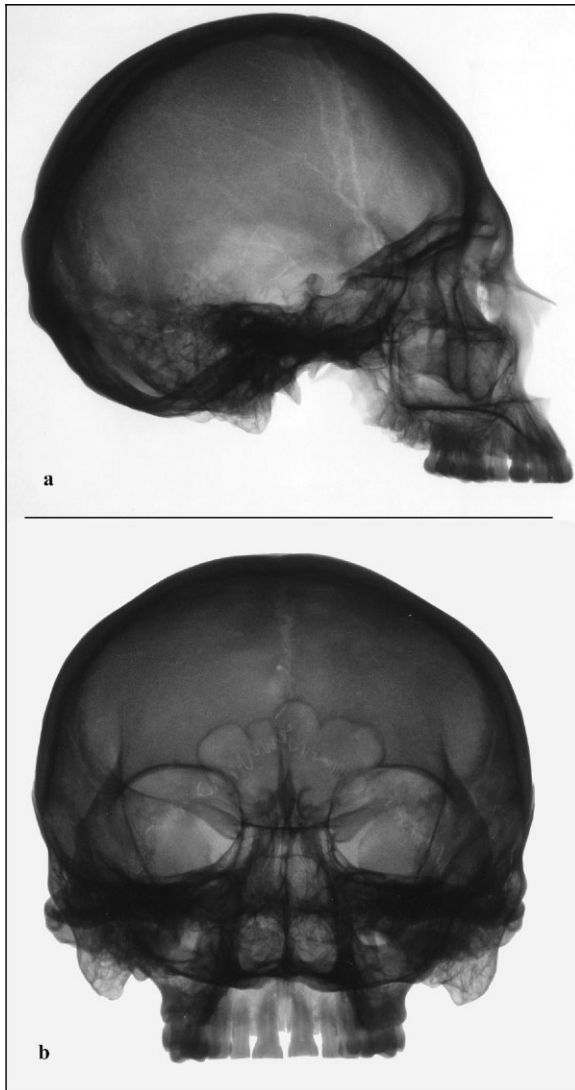


Figure 2. (a) Medial-lateral and (b) anterior-posterior radiographs of Motmot's cranium.

disarticulated remains of an adult male (Buikstra *et al.*, 2004.) Application of the newly-developed transition method (Milner *et al.*, 2000; Boldsen *et al.*, 2002) indicates that K'inich Yax K'uk' Mo' lived well past his fifth decade (Buikstra *et al.*, 2004).

The most impressive physical evidence of life-style for K'inich Yax K'uk' Mo' derives from an analysis of blunt force trauma that had been sustained during his adulthood (Buikstra *et al.*, 2004). He had suffered a 'parry' or 'nightstick' fracture to both bones of the right forearm

(Figure 3a and b). It is generally postulated that such fractures result from a direct blow to the forearm when the arm is pronated and raised in defence to shield the face (Merbs, 1989; Perry *et al.*, 1995; Galloway, 1999).

The fact that both fractures were not reduced is clear based on both gross examination and radiographic assessment (Figure 3a and b). The fragments of the right radius reunited and the resultant bony callus is well-organised and integrated, indicating that the fracture was stabilised and that the healing process was inactive at the time of death. The distal shaft was displaced proximally and healed in a position that shortened the bone by approximately 1 cm (Figure 3a and b). The left radius measures 246 mm, while the right radius measures approximately 236 mm. Despite the fracture and the healed malalignment, cortical bone thickness of the right radius appears unaffected. In fact, in comparison to the unaffected left radius (Figure 4), the right radius appears more radiodense. While this may be a result of the osteoblastic activity associated with healing, the distal half of the diaphysis is denser than the corresponding section on the left radius. While the right radial head suffered a small amount of post-depositional damage, a line of reactive bone along the margin of the head is visible. The distal epiphysis also demonstrates the development of radiodense arthritic bone (Figure 3a and b). This emargination is probably due to altered patterns of compressive and tensile loadings, perhaps to compensate for the complete ulna separation.

The fragments of the ulna did not reunite (Figure 3a and b). Interestingly, while there is arthritic lipping grossly visible throughout the elbow, wrist and hand, an indication that the insult did not result in complete disuse of the limb, the two fragments of the ulna are radiolucent compared with the denser radial fragments. The absence of trabecular bone in the distal portion is probably due to post-mortem perforation of the diaphysis, evident radiographically as a radiolucent oval shape near the metaphysis.

The thorax suffered a significant amount of restructuring, the apparent result of blunt force trauma. The caudal portion of the gladiolus was depressed, causing the superior portion to project ventrally and displacing the articulation to the

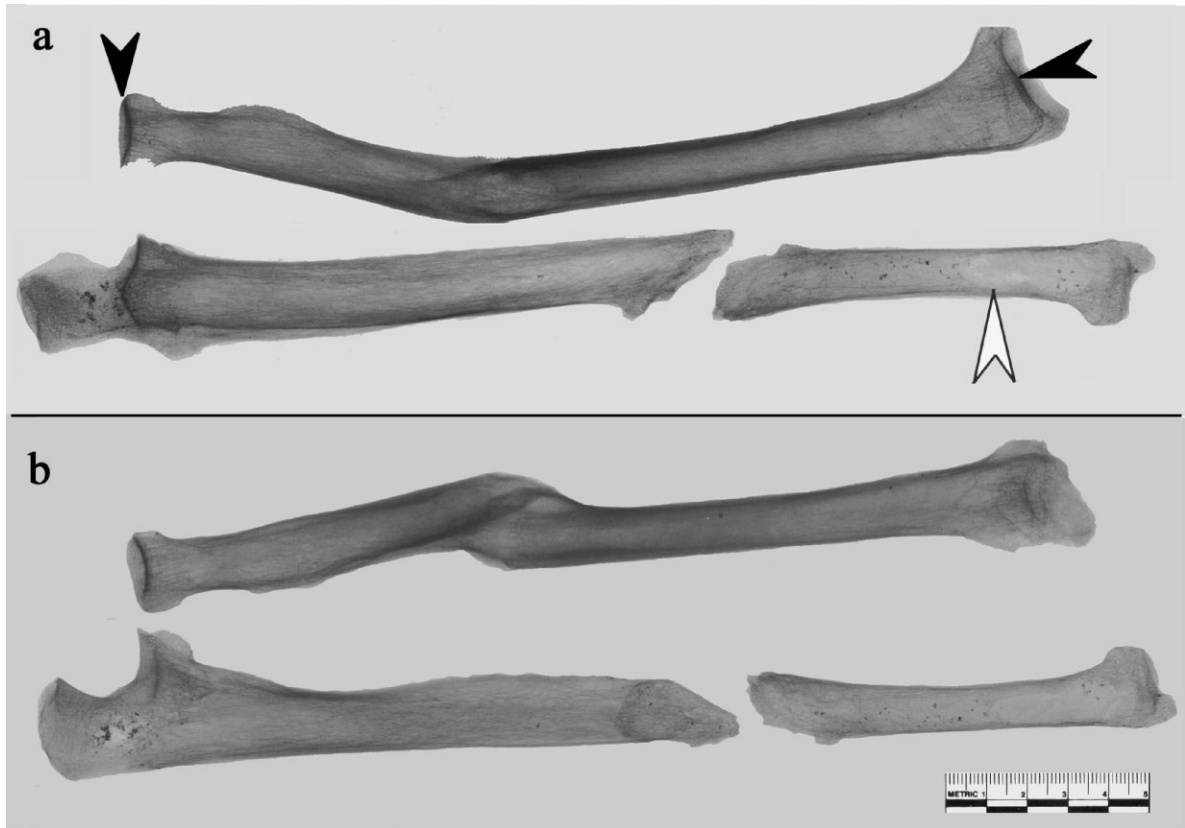

Figure 3. (a) Anterior-posterior radiograph of right radius and ulna and (b) medial-lateral radiograph of right radius and ulna. The white arrow points to a post-depositional radiolucency on the ulna as noted in text. Black arrows point to areas of reactive bone as noted in text.

dorsal surface of the gladiolus. Radiographically, both the inferior margin of the manubrium and the superior margin of the gladiolus demonstrate areas of radiodense bone, probably the result of this modified articulation (Figure 5b). The inferior portion of the gladiolus has suffered consider-

able post-depositional damage and is also obscured radiographically by cinnabar.

More than likely related to the above restructuring, the articulations between the manubrium and the clavicles were altered, forming new articular facets more laterally on the clavicles. There is



Figure 4. Anterior-posterior radiograph of left radius and ulna.

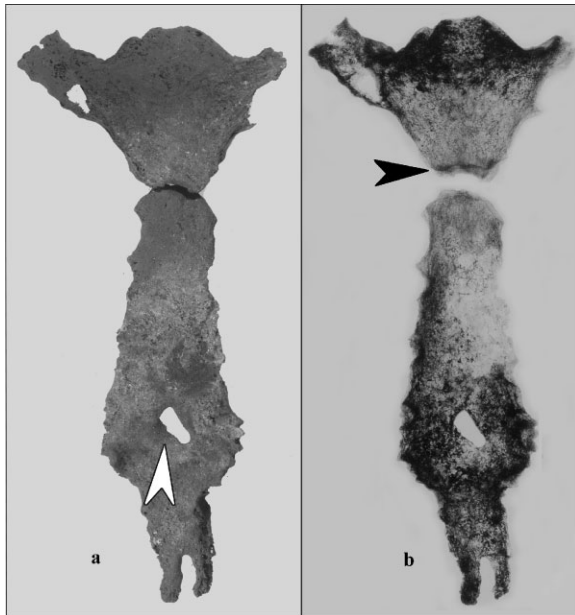


Figure 5. (a) Photograph of sternum (white arrow marks area of thinning as noted in text) and (b) anterior-posterior radiograph of sternum (black arrow marks formation of radiodense bone at altered manubrium and gladiolus articulation as noted in text).

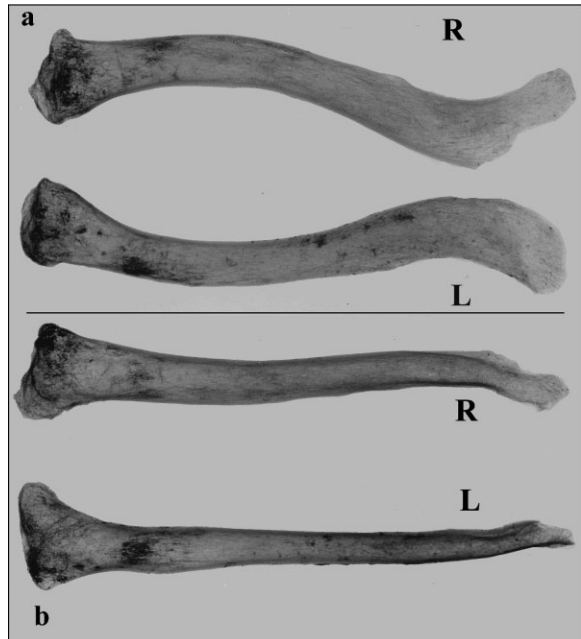


Figure 6. (a) Superior-inferior and (b) anterior-posterior radiographs of right and left clavicles.

an exuberant cartilaginous ossification, which may be due simply to their greater frequency in older individuals, but may also be related to altered articulations following trauma. Radiographic evaluation of the sternal articular surfaces on the manubrium is hampered by the presence of cinabar (Figure 5b). Grossly, both sternal ends are expanded, with the right being coarsened irregularly, appearing more disorganised and radiodense than the left (Figure 6a and b).

The most unusual example of blunt force trauma evident in K'inich Yax K'uk' Mo' involved the left shoulder. The superior third of the glenoid fossa and the coracoid process of the scapula separated from the remainder of the bone (Figures 7 and 8). The fracture was not reduced, and the bone segments never united. From Figures 7 and 8, we can see that the rim of the glenoid fossa appears disorganised. Upon gross examination (Buikstra *et al.*, 2004) it was noted that there were marked arthritic changes at the shoulder, including pronounced lipping of the humerus and eburnation of the inferior third of the humeral head, probably due to post-traumatic osteoarthritic development.

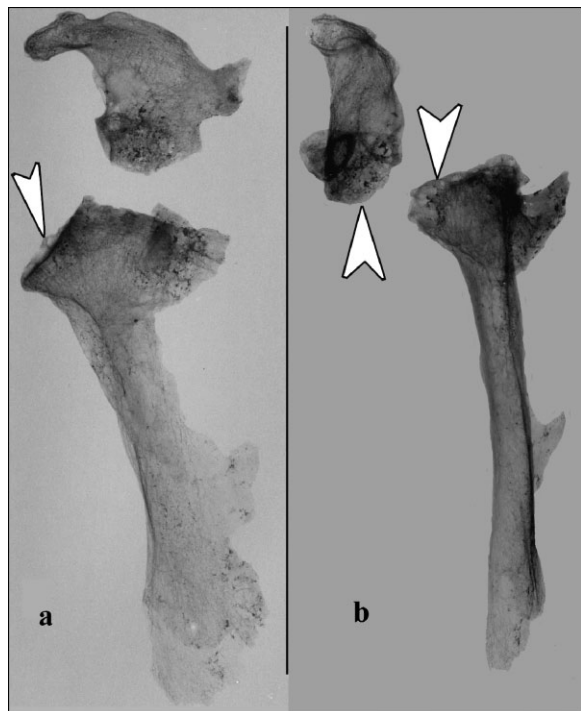


Figure 7. (a) Anterior-posterior radiograph and (b) medial-lateral radiograph of left scapula. Arrows mark areas of disorganised bone on glenoid fossa.

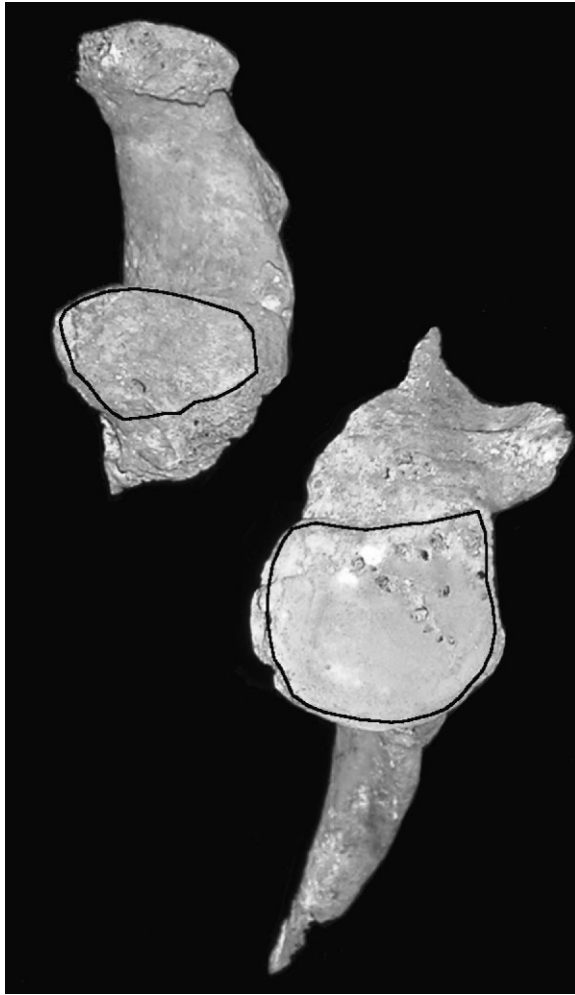


Figure 8. Medial-lateral photograph of left scapula demonstrating the degree to which the glenoid fossa was involved in the separation of the coracoid process.

The K'inich Yax K'uk' Mo' skeleton also displays a number of other, less radical, blunt force injuries (Buikstra *et al.*, 2004). The right fifth metacarpal demonstrates morphological changes concomitant with an unreduced fracture. Based on the degree of integration and organisation at the fracture site, the injury was not actively remodelling at death.

Other grossly observed fractures were not so readily visualised radiographically. One and perhaps as many as three ribs present well-healed fractures; however, given the amount of cinnabar that remained, it is difficult to observe radiographic evidence for these fractures. Grossly,

the posterior aspect of the right parietal displays evidence of a healed depressed fracture, but we were unable to visualise the fracture radiographically. The 11th thoracic vertebra is wedged anteriorly from a compression fracture, which produced a 30 to 45 degree kyphosis, but again, given a thick layer of cinnabar, no further refinement is possible. Finally, there is a vertical fracture through the distal phalanx of the right great toe.

Other disorders documented by Buikstra *et al.* (2004) were also difficult to assess radiographically, either due to the presence of cinnabar or the poor quality of the bone which produced non-diagnostic radiographs. Within the spinal column, the joint between the seventh cervical and first thoracic vertebra is arthritic, with marked porosity and eburnation of the articular facets. Rib facets in the lower thoracic region are expanded and lipped. There are visible differences in bone density between the right and left metatarsals (Figure 9). While post-depositional damage to the right fourth and fifth metatarsals could account for this generalised loss of bone density, the diaphyses of the second and third metatarsals are intact. The aetiology of this loss of bone density remains equivocal. There are no accompanying externally visible defects such as increased porosity or grossly visible leading edges of infection which might account for the observed unilateral bone density loss.

The Motmot interment

The primary interment within the Motmot tomb is a remarkably well-preserved skeleton of a female who died during young adulthood. Her remains are notable for their gracility, including narrow long bone diaphyses and only slightly developed muscular attachments. Despite her gracile appearance the bones exhibit normal radiographic density. There is no evidence that the Motmot individual suffered from osteoporosis, osteopenia, or experienced cortical or trabecular bone loss due to disuse atrophy.

The Motmot individual suffered a 'parry' or 'nightstick' transverse fracture to her right forearm (Figure 10). Cortical and trabecular bone thickness appear normal. The bony callus at the ulnar midshaft is well-integrated and was not

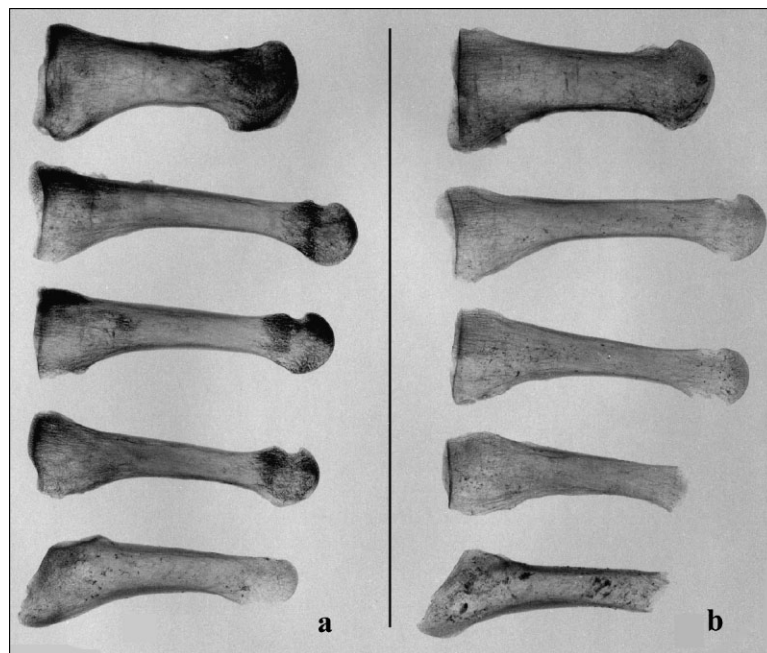


Figure 9. Medial-lateral radiographs of (a) left and (b) right metatarsals.

actively remodelling at the time of death. There was no displacement of the ulnar segments and the fracture healed in near perfect anatomical alignment.

Finally, we evaluated the possible fracture at the surgical neck of the right humerus. Radiographically, there was no indication of a fracture line at this site.

Discussion

K'inich Yax K'uk' Mo'

As stated in the introduction, the purpose of the radiographic assessment of the skeletal remains recovered from the Acropolis at Copan was to enhance and potentially expand the conclusions based upon a gross examination of the material. This includes the documentation of previously unobserved pathological indicators and the refinement and verification of previously observable indicators. The last includes structural bony changes that would have been the result of altered physiological function, such as disuse atrophy and cortical or trabecular bone thinning or thickening.

It is not possible to define more precisely the timing or sequence of the traumata beyond that suggested by gross evaluation. For *K'inich Yax K'uk' Mo'*, in the absence of any epiphyseal dislocation due to trauma, it would appear that the major injuries to the thorax and upper limbs occurred after approximately 25 years of age.

Based upon the radiographs it is possible to refine our understanding of potential behavioural and structural changes due to the traumata observed in these individuals. We infer from the radiographs that the insult to the right radius of *K'inich Yax K'uk' Mo'* did not result in disuse atrophy. Cortical thickness remains normal and there is gross and radiographic evidence for the development of arthritic lipping at the articular surfaces. Interestingly, despite this gross evidence of arthritic changes associated with the radius, the ulna lost a significant amount of its cortical bone thickness. In general, cortical bone density at this site is low, an indication that it was not subject to pressure or irritation resulting from continued use. It is possible that the radius acted as an internal splint, preventing significant movement at the site. There is evidence that some contact existed between the portions of the ulna based upon the lipping present on both surfaces. Therefore, while

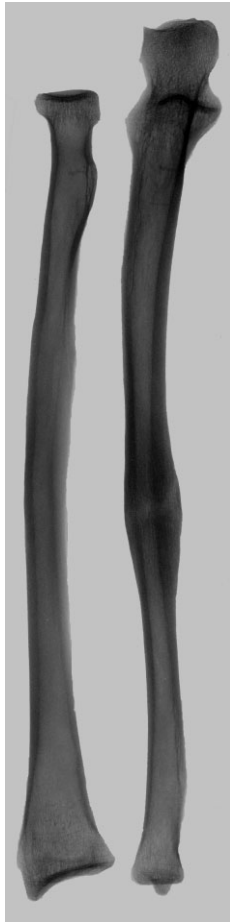

Figure 10. Anterior-posterior radiograph of Motmot individual's right forearm.

the radius displays evidence of continued use, the ulna appears to have atrophied.

Results from experimental pig and dog long bone osteotomies (Chamay & Tschantz, 1972; Goodship *et al.*, 1979) provide a possible explanation for this disparate reaction in cortical bone thickness. Their research indicates that the rendering of either the radius or the ulna useless results in diaphyseal hypertrophy in the unaffected bone. The extension of these results to the current discussion, however, must be tempered. In the experimental pigs and dogs, the radius and ulna are weight-bearing bones and therefore are more susceptible to, and accommodate more rapidly, shifts in compressive and tensile loads. Further experimental data would be needed to investigate the same relationship in non-weight-bearing paired long bones.

The behavioural implications that led to the structural alterations evident in the clavicle and manubrium present a diagnostic challenge. The event that caused these alterations depressed the caudal portion of the gladiolus, consequently causing the superior portion to project ventrally, subsequently displacing the articulation to the dorsal surface of the gladiolus. The same event probably affected the sternal articulations of the clavicles. Both clavicular articulations are enlarged, roughened and radiodense. It is possible that the thoracic restructuring may have been the result of injuries sustained during a ballgame (Buikstra *et al.*, 2004).

The fractures of the shoulder girdle probably resulted in radical structural and functional changes. The two scapular fragments were sufficiently displaced such that they never united. This displacement may have affected the stabilising properties of the ligaments and muscles, and continued use of the joint would have prevented the fragments from healing as a unit. While this fracture could have disrupted the shoulder's physiology, possibly leading to degenerative changes and paralysis, there is no evidence of disuse atrophy in the left upper limb. Evidence for disuse atrophy would be a generalised loss of cortical density, but it is observed from the radiographs that the glenoid fossa continued to serve as a point of articulation (Figure 7). Moderate arthritic development in the elbow, wrist and hand also indicates that the limb continued to be used.

Given that there are no size or shape differences between the left and right scapula, it is unlikely that the injury to the left scapula was due to epiphyseal separation during childhood. From the modern medical literature we know that such scapular fractures are rare, but may be the result of high-energy impacts (Rogers, 1982; Neer & Rockwood, 1984; Goss, 1992, 1995; Herscovici *et al.*, 1992; Zuckerman *et al.*, 1993; Ideberg *et al.*, 1995; Galloway, 1999), such as automobile, pedestrian and motorcycle accidents (Zuckerman *et al.*, 1993: 271; Stephens *et al.*, 1995: 440). Shoulder trauma, rib and clavicle fractures are also commonly involved in these types of accidents (Goss, 1992: 299; Herscovici *et al.*, 1992; Zuckerman *et al.*, 1993: 271; Stephens *et al.*, 1995).

Buikstra *et al.* (2004) suggested three plausible scenarios that may have resulted in the observed pattern of scapular fractures. The first is a direct blow to the shoulder, at the point or in the region of the coracoid process (DePalma, 1983; Neer & Rockwood, 1984). Goss (1995: 270) associated fractures of the base of the coracoid with direct blows to the shoulder in the more violent 'stick' sports such as lacrosse and hockey. Secondly, this fracture pattern may have resulted from a fall with the arm adducted, with the shoulder striking the ground or another hard surface. Lastly, K'inich Yax K'uk' Mo' could have fallen toward the left with his arm extended and his hand outstretched to break the impact.

All of the fractures evident within the K'inich Yax K'uk' Mo' remains are either healed, permanently in a state of non-union, or are associated with arthritic bony development. K'inich Yax K'uk' Mo' obviously led a very active and at times dangerous life. The trauma indicators identified above provide hints as to the nature of his life before his arrival at Copan and his subsequent consolidation of power. Despite dramatic evidence that points to numerous broken bones, he continued an active lifestyle, reaching an estimated age of greater than 50 years. Not only would his participation in the more pragmatic aspects of kingship be vital (conquest and consolidation), but his continued participation in the Maya ballgames would have been an important aspect in his ascendancy to power and the ritual continuation of Maya life and death cycles.

Motmot

Radiographic assessment of epiphyseal closure supported the young adult age estimate for the Motmot individual. Given this estimate, we can speculate that the parry fracture suffered by the Motmot individual happened before approximately 25 years of age.

As noted, the skeletal remains of the Motmot interment are quite gracile, lacking prominent muscle markings. Based upon the radiographs, cortical and trabecular bone thickness appears normal, leading us to conclude that her gracility was not due to osteoporosis or osteopenia. Based upon the calculation of cross-sectional geometric

properties of the humeri, we were able to document a slight asymmetry in humeral medullary area, suggesting a relatively expanded medullary area at the midshaft of the right humerus.

Buikstra *et al.* (2004) report stable isotopic evidence that the principal interment in the Motmot tomb apparently spent her youth further north, in the Central Peten, perhaps around Tikal. Her presence in a tomb that included an initial sacrifice and then a subsequent deposition of two human heads indicates that she was an important personage, perhaps herself an elite political prisoner sacrificed at Copan. Whatever her history, the Motmot individual did suffer a significant injury to the right forearm. The injury probably occurred sometime during late adolescence or early adulthood based upon the degree of healing and her estimated age. It is possible that the injury was reduced and splinted, given that there is no notable alignment abnormality. Whether this insult was due to violence or accident, however, must remain speculative.

Conclusions

When used in conjunction, gross and radiographic assessment of trauma and pathological processes greatly enhances our understanding of past lifeways. Indeed, dependence on the gross observation of such processes may hide a vital part of the picture. At the simplest level, radiographic documentation of skeletal remains may reveal previously undocumented lesions, trauma, or pathological process. Alternatively, conclusions based upon gross examination may be refuted or refined. In the case of the Motmot individual, we were able to eliminate the possibility that she suffered from osteopenia or osteoporosis, conclusions that could be suggested by gross examination alone. This led to alternative explanations that dealt more with behaviour or social context. Additionally, for the Motmot individual, we were able to speculate, based upon the nature of the healed right ulna, that the injury may have been reduced and splinted. While it is not unexpected that ancient people practised first aid, it is significant that palaeopathology and palaeoradiography can indirectly demonstrate treatment.

Structural changes to cortical or trabecular bone can provide important hints in the reconstruction of activity-related shifts in behaviour subsequent to trauma or pathological process. K'inich Yax K'uk' Mo' obviously suffered numerous insults during his long life. These injuries probably altered the physiological function of the affected areas, but they do not appear to have resulted in complete disuse of the affected area. The fracture to the right radius did not adversely affect cortical bone thickness, yet at the same time the ulna appears to have lost cortical bone thickness.

From experimental data, researchers have shown that hypertrophic compensation can occur in paired bones (Chamay & Tschantz, 1972; Goodship *et al.*, 1979), although these results need to be extended to non-weight-bearing limbs. Arthritic development at the corresponding elbow and wrist indicate continued use of the arm. Furthermore, calculation of cross-sectional geometric property from orthogonal radiographs (Biknevicius & Ruff, 1992) indicates that the humeri experienced subtle mechanical alteration following trauma. The results suggest that despite the fracture of both right forearm bones, K'inich Yax K'uk' Mo' retained near normal use of the arm. While loss of cortical bone is positively correlated with age (Ruff & Jones, 1981), bone loss in the right humerus was accelerated relative to the left humerus. At the same time, cortical bone was redistributed away from the neutral axis of the long bone in order to maintain mechanical integrity.

In conjunction with the gross evaluation, we were able to further our understanding of the behavioural implications behind such trauma. The unique suite of trauma evident on K'inich Yax K'uk' Mo' increases our understanding of ancient Maya lifeways in general, and of the nature of elite social behaviour at Copan in particular.

Acknowledgements

Funding for the original osteological analysis of the remains came from the National Geographic Society, the National Science Foundation, and Texas A&M University. Permission for the study has been granted by Oscar Cruz and the Instituto

de Hondureño de Antropología y Historia and by Robert Sharer, William Fash and Barbara Fash of the Copan Acropolis Project. The assistance of Ellen Bell, Marcello Canuto, Lynn Grant, Christopher Powell, David Sedat and Loa Traxler has been essential to the success of the project. The radiographic portion of the research was made possible by funding from FAMSI and the Ahau Foundation. We would also like to thank three anonymous reviewers for their comments which have greatly improved this manuscript. KCN would like to thank Jerry Conlogue, Ronald Beckett and Rick Carlton for exposing him to palaeoradiography.

References

- Armstrong CW. 1989. *Pathological Analysis of Long Bones within the Tipu Population*. Master's thesis, State University of New York at Plattsburgh, Plattsburgh.
- Bell EE, Sharer RJ, Traxler LP, Sedat DW, Carrelli CW, Grant LA. 2004. Tombs and burials in the Early Classic Acropolis at Copan. In *Understanding Early Classic Copan*, Bell EE, Marcello AC, Sharer RJ (eds). University of Pennsylvania Museum of Archaeology and Anthropology: Philadelphia; 131–157.
- Biknevicius AR, Ruff CB. 1992. Use of biplanar radiographs for estimating cross-sectional geometric properties of mandibles. *Anatomical Record* **232**: 157–163.
- Boldsen JL, Milner GR, Konigsberg LW, Wood JW. 2002. Transition analysis: a new method for estimating age-indicator methods. In *Paleodemography: Age Distribution from Skeletal Samples*, Hoppa RD, Vaupel JW (eds). Cambridge University Press: New York; 72–106.
- Buikstra JE, Price TD, Burton JH, Wright LE. 2004. Tombs from Copan's Acropolis: a life history approach. In *Understanding Early Classic Copan*, Bell EE, Marcello AC, Sharer RJ (eds). University of Pennsylvania Museum of Archaeology and Anthropology: Philadelphia; 258–295.
- Canuto MA, Bell EE, Sharer RJ. 2004. Understanding Early Classic Copan: a Classic Maya center and its investigation. In *Understanding Early Classic Copan*, Bell EE, Marcello AC, Sharer RJ (eds). University of Pennsylvania Museum of Archaeology and Anthropology: Philadelphia; 1–14.
- Chamay A, Tschantz P. 1972. Mechanical influences in bone remodeling: experimental research on Wolff's Law. *Journal of Biomechanics* **5**: 173–180.

- Cohen MN, O'Connor K, Danforth ME, Jacobi KP, Armstrong C. 1997. Archaeology and osteology of the Tipu site. In *Bones of the Maya: Studies of Ancient Skeletons*, Whittington SL, Reed DM (eds). Smithsonian Institution Press: Washington; 78–86.
- Conlogue G, Nelson A. 1999. Polaroid imaging at an archaeological site in Perú. *Radiologic Technology* 70(3): 244–250.
- DePalma AF. 1983. *Surgery of the Shoulder* (3rd edn). J. B. Lippincott: New York.
- Fash WL, Fash BW, Davis-Salazar KL. 2004. Setting the stage: origins of the Hieroglyphic Stairway Plaza on the Great Period Ending. In *Understanding Early Classic Copan*, Bell EE, Marcello AC, Sharer RJ (eds). University of Pennsylvania Museum of Archaeology and Anthropology: Philadelphia; 65–83.
- Galloway A (ed.). 1999. *Broken Bones: Anthropological Analysis of Blunt Force Trauma*, Charles C. Thomas: Springfield.
- Goodship AE, Lanyon LE, McFie H. 1979. Functional adaptation of bone to increased stress. *Journal of Bone and Joint Surgery* 61-A: 539–546.
- Goss TP. 1992. Fractures of the glenoid cavity: current concepts review. *Journal of Bone and Joint Surgery* 74-A: 299–305.
- Goss TP. 1995. Fractures of the shoulder complex. In *Upper Extremity Injuries in the Athlete*, Pappas AM, Walzer J (eds). Churchill Livingstone: New York; 259–276.
- Herscovici D, Fiennes AG, Allgöwer M, Rüedi TP. 1992. The floating shoulder: ipsilateral, clavicle and scapular neck fractures. *Journal of Bone and Joint Surgery* 74-B: 362–364.
- Ideberg RS, Grevsten S, Larsson S. 1995. Epidemiology of scapular fractures: incidence and classification of 338 fractures. *Acta Orthopaedica Scandinavica* 66: 395–397.
- Merbs CF. 1989. Trauma. In *Reconstruction of Life from the Skeleton*, Iscan MY, Kennedy KAR (eds). Alan R. Liss, Inc: New York; 161–189.
- Milner GR, Boldsen JL, Wood JW. 2000. Paleodemography. In *Biological Anthropology of the Human Skeleton*, Katzenberg MA, Saunders SR (eds). Wiley-Liss: New York; 467–497.
- Neer CS, Rockwood Jr. CA. 1984. Fractures and dislocations of the shoulder. Part I: fractures about the shoulder. In *Fractures in Adults*, Rockwood CA, Green DP (eds). J. B. Lippincott: Philadelphia; 675–721.
- Perry CR, Elstrom JA, Pankovich AM (eds). 1995. *Handbook of Fractures*. McGraw Hill: New York.
- Rogers LF. 1982. *Radiology of Skeletal Trauma*. Churchill Livingstone: New York.
- Ruff CB, Jones HH. 1981. Bilateral asymmetry in cortical bone of the humerus and tibia—sex and age factors. *Human Biology* 53: 69–86.
- Saul JM, Saul F. 1997. The Preclassic skeletons from Cuello. In *Bones of the Maya: Studies of Ancient Skeletons*, Whittington SL, Reed DM (eds). Smithsonian Institution Press: Washington; 28–50.
- Schele L. 1986. *The Founders of Lineages at Copan and other Maya Sites*. Copan Note 8. Report prepared for the Instituto Hondureño de Antropología e Historia, Tegucigalpa and the Copan Acropolis Project, Austin TX.
- Sharer RJ. 1997. *The Foundation of the Ruling Dynasty at Copan, Honduras: The Early Acropolis and Mesoamerican Interaction*. Paper presented at the symposium, A Tale of Two Cities: Copan and Teotihuacan, Harvard University, Cambridge, MA.
- Sharer RJ, Traxler LP, Sedat DW, Bell EE, Canuto MA, Powell C. 1999. Early Classic architecture beneath the Copan Acropolis. *Ancient Mesoamerica* 10: 3–23.
- Stephens NG, Morgan AS, Corvo P, Bernstein BA. 1995. Significance of scapular fracture in the blunt-trauma patient. *Annals of Emergency Medicine* 26: 439–442.
- Stuart D, Schele L. 1986. *Interim Report on the Hieroglyphic Stair of Structure 26*. Copan Note 17. Copan Mosaics Project and the Instituto Hondureño de Antropología e Historia: Copan Honduras.
- Whittington SL. 1989. *Characteristics of Demography and Disease in Low Status Maya from Classic Period Copan, Honduras*. Unpublished PhD dissertation. Pennsylvania State University: University Park.
- Zuckerman JD, Koval AS, Cuomo F. 1993. Fractures of the scapula. *Instruction Course Lectures* 42: 271–281.