

Mortuary Behaviour Reconstruction through Palaeoentomology: A Case Study from Chachapoya, Perú

K. C. NYSTROM,^{a*} A. GOFF^a AND M. LEE GOFF^b

^a *Department of Anthropology, University of New Mexico, Albuquerque, NM 87131, US*

^b *Forensic Science Program, Chaminade University of Honolulu, Hawaii, US*

ABSTRACT This paper explores the contribution that applied forensic entomology can make to our understanding of prehistoric mortuary behaviour. Samples of insect remains were recovered from a mummy bundle that has been attributed to the Chachapoya people who occupied the northern highlands of Perú from ca. AD 800 to ca. AD 1532. The insects were identified to the family level and used to create a hypothetical timeline of post-mortem interval before the construction of the mummy bundle. The individual in question suffered from a number of blunt force insults to the head, followed by two and possibly three trepanation events. We speculate the initial insect colonisation to have taken place almost immediately following injury and subsequent surgery, occurring before the individual's death. Insect succession patterns and timing estimates for the appearance of periosteal reactive bone suggest that the individual was wrapped shortly following death. The application of such modern forensic techniques holds vast promise for addressing issues concerning Chachapoya mortuary behaviour and, further, these results can expand our understanding of mummy studies in general. Copyright © 2005 John Wiley & Sons, Ltd.

Key words: palaeoentomology; Chachapoya; mortuary behaviour reconstruction; trepanation

Introduction

The reconstruction of the mortuary behaviour of prehistoric groups is generally based upon the examination of body processing techniques (mummified versus skeletonised), orientation of the body and the grave (e.g. in relation to the cardinal directions, other burials within the same cemetery), the type of funerary context (e.g. midden burials, mound burials, house burials), its association with other contexts (e.g. residential, public, private), and grave goods (e.g. type, quality, quantity, origin). These characteristics of behaviour, however, can be rather broad brush-strokes. Ethnographic records, when available,

may contribute to our understanding and serve as a guide, but should not be viewed as a more objective data source. There is yet another source which is often available to anthropologists, yet to date has not been widely exploited (see Faulkner (1986) and Nelson (1998) for another example of palaeoforensic research). The examination and identification of insects associated with human remains can provide another level of detail to the reconstruction of funerary behaviour.

As a body decomposes it provides resources to a variety of arthropods that sequentially colonise the remains. The pattern of colonisation by insects depends upon the rate and manner of body decomposition, as the two are inextricably linked. Deviations from this pattern may represent instances of human or cultural intervention in the decomposition process. For example, in a modern forensic setting, the movement and

* Correspondence to: Department of Anthropology, University of New Mexico, Albuquerque, NM 87131, USA.
e-mail: knystrom@unm.edu

storage of a body will alter succession patterns, and therefore this behaviour can be deduced based upon the type of insects found with the body. In this paper, we are interested in applying principles derived from forensic entomology to the archaeological record in the reconstruction of mortuary behaviour. In particular, we seek to use insect materials to reconstruct the post-mortem interval which ultimately ended in the construction of a mummy bundle. Our study focuses on a Chachapoya mummy bundle from the northern highlands of Perú (Figure 1).

Chachapoya mortuary behaviour

Beyond the description provided by Guillén (1998) on the mummification process observed at the Laguna de los Cóndores, very little data exists from the region concerning the nature or extent of post-mortem body processing. The mummy bundles from the Laguna de los Cóndores were sub-

jected to a sophisticated artificial process, which included evisceration and perhaps some chemical treatment of the skin, followed by several layers of textile wrappings (Guillén, 1998). Secondly interred skeletal remains were also recovered from the *chullpas* at the Laguna de los Cóndores site (Guillén, 1998; von Hagen, 2002). While only secondarily interred skeletal remains were recovered from the *chullpas* at Los Pinchudos, Morales and colleagues (Morales *et al.*, 2002; Church & Morales, 2001) concede that they cannot unequivocally eliminate the possibility that mummies existed at some point at the site. Human remains recovered from a *chullpa* at the Laguna Huayabamba site contained mummified, secondarily interred skeletonised remains, and the primary interment of a number of children (Muscutt, 2003; Nystrom, 2003). Several of the mummies have not been eviscerated, although at this time it is impossible to state unequivocally whether or not these mummies were artificially produced.

Gil (1936: 236) reported on anthropomorphic sarcophagi containing cadavers set in a tightly flexed position. Langlois (1934, 1940a,b) described the remains he observed as being a mummy wrapped in cotton textile. Kauffmann and colleagues (Kauffmann *et al.*, 1989; Kauffmann, 2002) described the remains in one of the largest sarcophagi as a mummy wrapped in textiles, seated in flexed or extended position within an animal skin that covered the inferior half of the body. It is not known whether these mummies would be considered artificial or natural.

The paucity of data on body processing is due in part to the often disturbed context and nature of the mummy bundles. Grave robbers tear open mummy bundles in their search for gold, exposing the bodies inside to the elements. While this activity obviously destroys contextual evidence, it is still possible to glean important data pertaining to body processing. The individual examined in this case study is one such disturbed mummy, and emphasises the type and quality of data that can be gathered.

Description of individual

The data for this case study come from a single adult female mummy bundle currently housed at

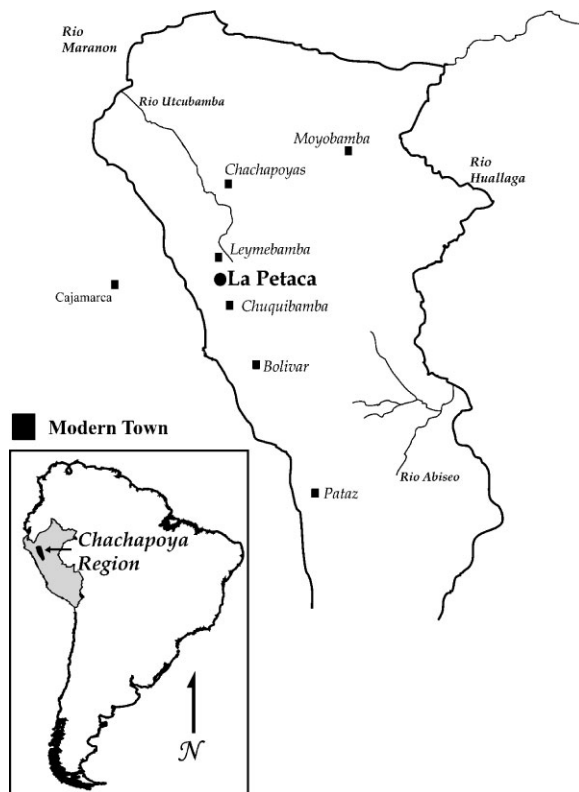


Figure 1. Map of Chachapoya region.

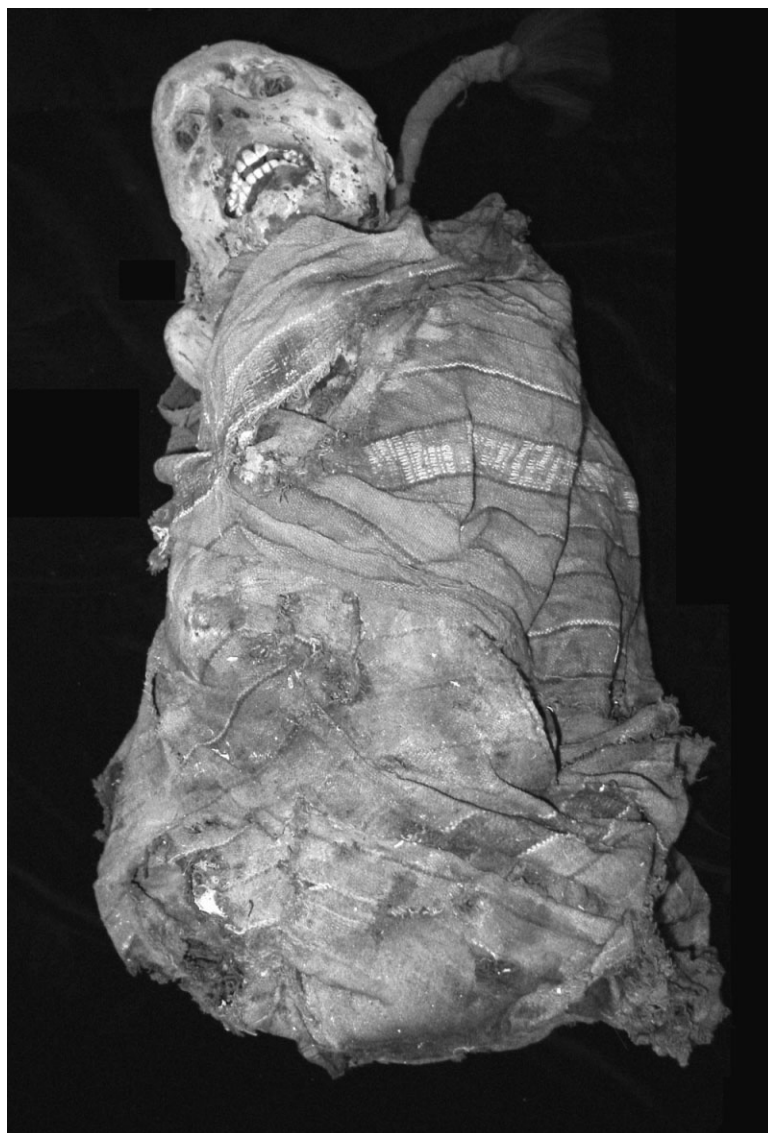

Figure 2. Chachapoya mummy bundle from which insect remains were recovered for use in this study.

the Instituto Nacional de Cultura (INC) Museum in Chachapoyas, Perú (Figure 2). It appears that the mummy was originally from the site of La Petaca (Figure 1), yet more detailed information on the original condition and context of the mummy is unknown. The mummy was taken from its cliff-side resting-place by students from Celendin, Perú, and spent some time at the INC in Cajamarca (Schjellerup, 1997: 198). The site of La Petaca contains both pre-Inka Chachapoya and Inka contact period archaeological material. In general, the funerary component of the site is

highly disturbed, with a number of the observable burial *chullpas* having collapsed. To this day, however, remarkably well-preserved mummified and skeletal remains are observable.

As observed by the principal author in 2003, the mummy is wrapped in woven cotton textiles, decorated with geometric designs coloured in blues, reds, whites and browns. The individual is tightly flexed and it is difficult to visualise the interior of the bundle. The head of the individual is fully exposed, with a large section of the occipital and posterior parietal bones missing.

A considerable amount of soft tissue remains attached to the head, including a large mass of brain tissue. When viewed anteriorly, the left side of the face appears swollen. Upon closer examination, the flesh is perforated by a multitude of insect holes, and numerous insect casings are present. The brain tissue also contains large numbers of insect casings. Pictures taken by Schjellerup (1997: 198) and Muscutt (1998) suggest that the individual was in similar condition as of 1998.

The individual suffered two blunt force insults, with subsequent surgical intervention. Fracture #1 is near the border of the frontal and left parietal bones, is rounded or oval in shape, and is approximately 4 cm in diameter (designated F#1 on Figure 3). Both the inner and outer tables are affected and the defect is internally bevelled. The piece of bone was missing at the time of examination. Fracture #2 is much more easily visualised on the interior surface (designated F#2 on Figure 3). This fracture is posterior to the first, is rounded or oval in shape, and is approximately 4 cm in diameter.

There are two definitive examples of trepanation. The first example (designated T#1 on Figure 4) is approximately 1 cm² and is located 3 cm from the sagittal suture on the right parietal. The edges on the outer table are rough, while the inner table edges are much sharper. The outer

table on the lateral side of the trepanation is roughened and probably represents the presence of reactive bone, possibly a periosteal reaction to the cutting of the bone. The second trepanation (designated T#2 on Figure 5) is only visible from the interior of the cranium, for it is covered externally by a flap of scalp and is superior, anterior and medial in relation to Fracture #2. The perforation is located on the left parietal just posterior to the coronal suture and is approximately 1 cm².

Finally, there are three lesions observable that cannot be unequivocally defined as trepanations or fractures. The first is posterior to T#2 on the left parietal. It cannot be visualised exteriorly, being covered by skin, but interiorly its edges are rounded and rough (designated L#1 on Figure 5). Palpation of the outer table at this spot suggests that it did not fully perforate the skull. It is possible that this abnormality represents a purely osteolytic reaction, perhaps due to increased intracranial pressure or infection. The second lesion (designated L#2 on Figure 4) is medial to T#1 on the right parietal and is immediately adjacent to the sagittal suture. The hole is irregular, with one straight (anterior) edge, while the others are slightly curved. The interior edges are rough and may have been actively remodelling at the time of death. The third lesion (designated L#3 on Figure 4) is posterior to L#2 on the right

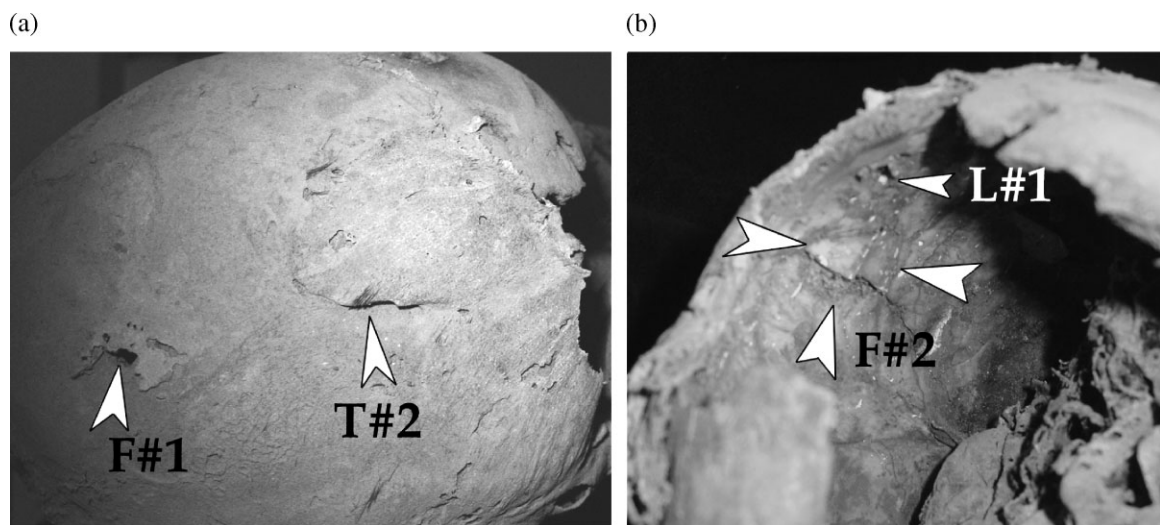


Figure 3. (a) Cranial depression Fracture #1 and (b) cranial depression Fracture #2.

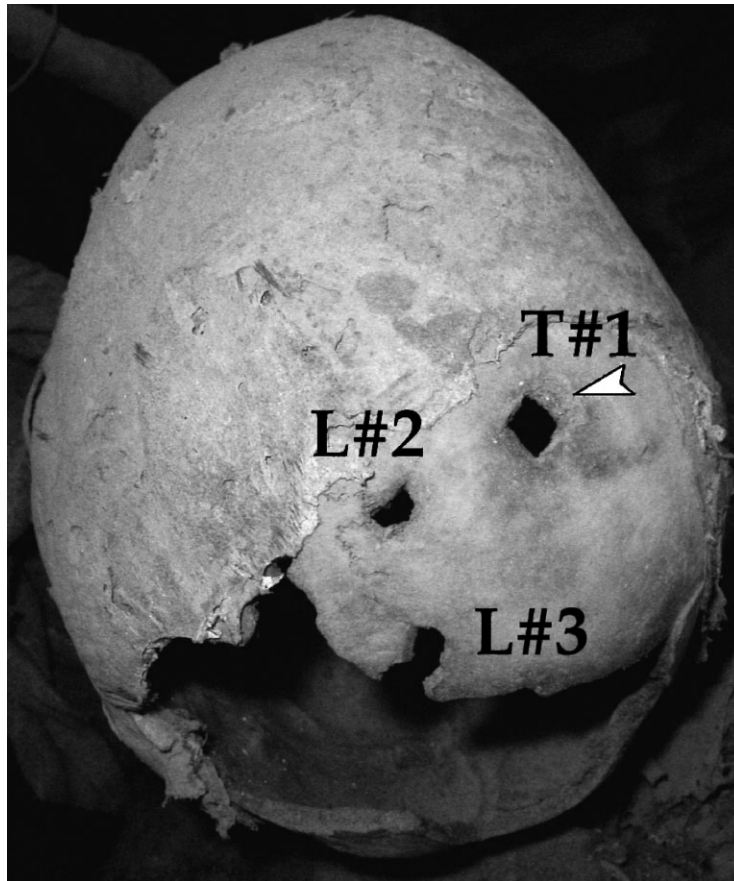


Figure 4. External view of posterior cranium. Trepanation #1 and Lesions #2 and #3 are marked. The white arrow adjacent to Trepanation #1 points to the area of periosteal reaction.

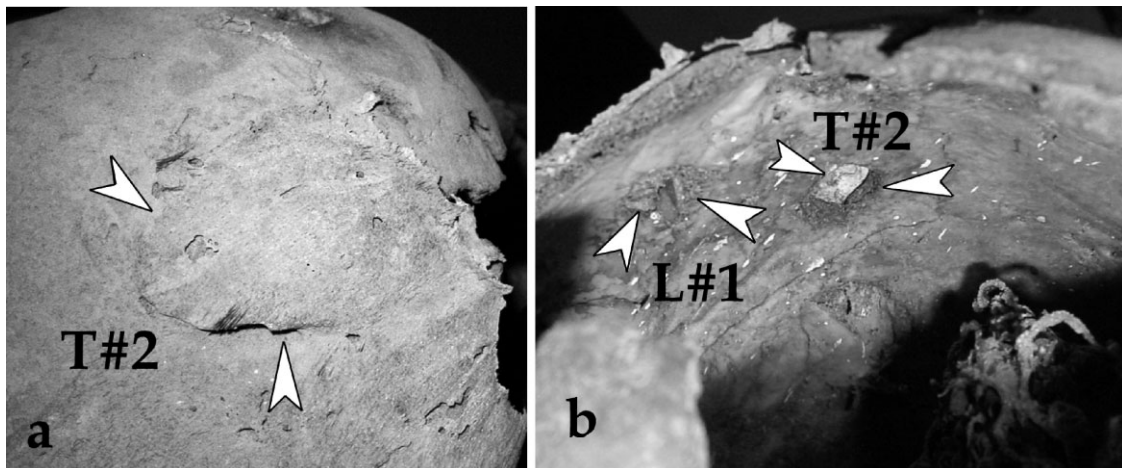


Figure 5. (a) External view of skin flap that covers Trepanation #2 (arrows point to edge of skin flap) and (b) internal view of Trepanation #2. The spatial relationship to L#1 is also indicated.

parietal immediately adjacent to the sagittal suture. The last two insults appear similar to the trepanations discussed above. The posterior edge of L#3 appears to have been damaged when the posterior portion of the cranium went missing.

The majority of the occipital and portions of the right and left parietal bones are missing, exposing the cranial cavity. This section was probably the result of post-mortem damage, possibly incurred during the removal of the textiles wrapping the head and the subsequent transport of the bundle from its original location. The presence of the damage to L#3 suggests that the loss of this large section of the skull occurred after the trepanations.

Body decomposition and entomology

There have been numerous studies of decomposition conducted in a variety of habitats. These include studies conducted in island habitats (Early & Goff, 1986; Tullis & Goff, 1987; Hewadikaram & Goff, 1991; Richards & Goff, 1997; Avila & Goff, 1998; Shalaby *et al.*, 2000), tropical continental habitats (Cornaby, 1974; Coe, 1978; Jiron & Cartin, 1981; Braack, 1987) and temperate continental habitats (Bornemissza, 1957; Reed, 1958; Payne, 1965; Rodriguez & Bass, 1983; Anderson & Van Laerhoven, 1996). The eastern montane forests of the Chachapoya region in which the site of La Petaca is located (approx. 3000 masl), ranges in elevation from 1500 to over 4000 masl (Schjellerup *et al.*, 2003). Average annual temperatures range from 9°C to 25°C, with an average annual precipitation of 1000 to 4000 mm (Schjellerup *et al.*, 2003). Annual relative humidity at Añasco Pueblo (1900 masl) and Luz de Oriente (1100–1500 masl), both in Huambo Valley, was 85.7% and 67.3% respectively (Schjellerup *et al.*, 2003). Given these environmental conditions, decomposition most probably follows the classification system used by Goff (1993). This classification divides decomposition into five stages: fresh, bloat, decay, active decay, and skeletal.

The fresh stage, characterised by algor mortis, rigor mortis and livor mortis, begins at death and ends when bloating is first observed. This stage has ranged from a few hours in Belize (Goff, 2001)

to two days in Hawaii (Goff, 1993). The first insects to arrive are common flies in the families Sarcophagidae (flesh flies) and Calliphoridae (blow flies), and may be seen ovipositing or larvaepositing into body orifices minutes after death. Other orders that may be observed during this stage include Hymenoptera (wasps) and Formicidae (ants), and flies in the families Drosophilidae (fruit flies) and Muscidae (Hewadikaram & Goff, 1991; Shalaby *et al.*, 2000; Goff, 2001).

The bloat stage begins when putrefactive processes of decomposition cause the abdomen to inflate, producing a balloon-like appearance. This ranges from two days in Belize (Goff, 2001) to three days in Hawaii (Goff, 1993). This stage is characterised by a large number of insects and the development of maggot masses. Sarcophagids and Caliphorids continue to be prominent during this stage, while flies in the families Muscidae, Fanniidae, Dolichopodidae, Carnidae, Piophilidae and Sepsidae may also be observed. Additional orders include Hymenoptera and Coleoptera (beetles) in one or more of the following families: Carabidae, Staphylinidae, Silphidae, Cleridae and Dermestidae (Hewadikaram & Goff, 1991; Anderson & Van Laerhoven, 1996; Shalaby *et al.*, 2000; Goff, 2001).

The decay stage begins when a carcass releases pungent odours and begins to deflate. This stage ranges from three days in Belize (Goff, 2001) to 11 days in Hawaii (Shalaby *et al.*, 2000). The predominant insects during this stage are maggot masses and Coleoptera. Adult flies are less abundant during this stage, but may continue to frequent the body. Hide beetles in the families Histeridae and Dermestidae may appear in large numbers, especially if flesh begins to mummify. By the end of this stage, fly larvae will have completed their development and leave the carcass for pupariation (Shalaby *et al.*, 2000; Goff, 2001).

The post-decay stage is reached when only skin and bones remain. Maggots may still be present during the initial part of this stage, but the predominant taxa will be Coleoptera.

The skeletal stage is the final stage for which there is no end point. In this stage, only bones, some skin, and hair remain. During this stage

carrion-frequenting taxa will depart and the normal soil fauna for the area will gradually return.

Results

Samples of insect remains were recovered from the brain tissue of the individual (Figure 6). The sample weighed approximately 1 gram. The samples were sent to MLG at the Chaminade University of Honolulu for identification. Identifications were possible only to family level due to the condition of the specimens. Samples are deposited in the Forensic Sciences Laboratory, Chaminade University of Honolulu, Hawaii, as CUHFE #0217.

The major component of the sample consisted of empty puparia of a species of fly in the family Calliphoridae. No adult flies were present. Adult

parasitoid wasps from the family Diapriidae were present. These wasps are parasitoids of immature Diptera and adult wasps emerge from the puparia. Several empty puparial cases were present in the collection with the characteristic lateral emergence holes for these types of parasitoids. Also present in this sample were larval casings and a head capsule of Lepidoptera species. These casings were typical of species of moths in the family Tineidae, or clothes moths.

Discussion

Given the above results, there are several key points that will structure the following discussion:

- (1) The body was exposed long enough prior to wrapping for insect activity (Diptera) to

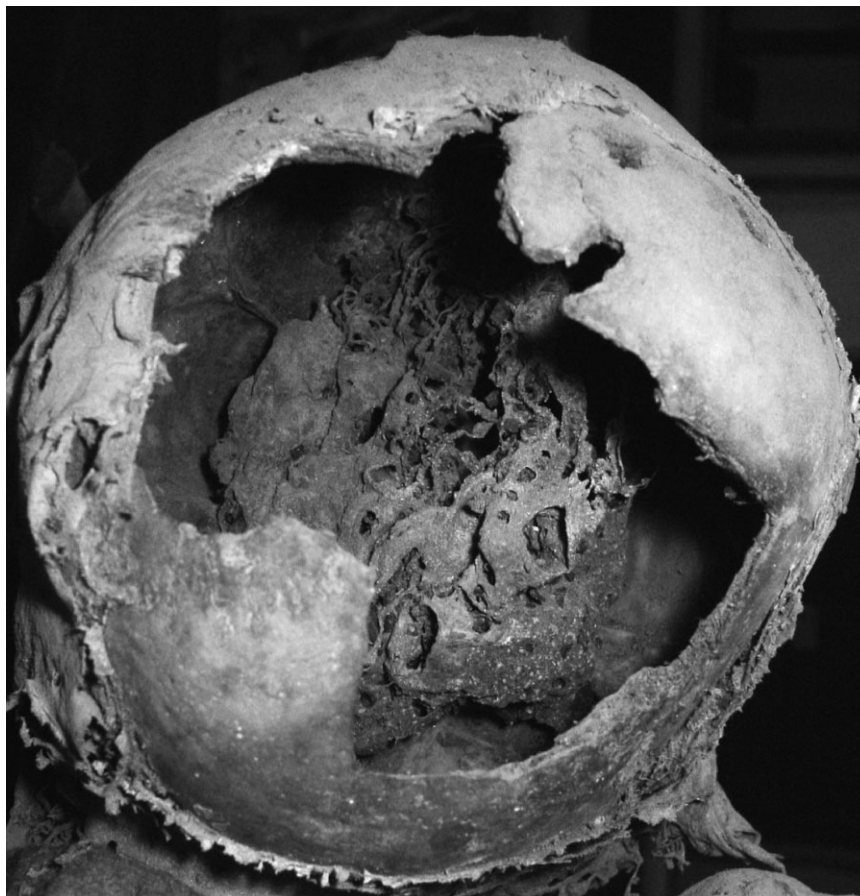

Figure 6. Preserved brain tissue with insect casings.

occur. These flies do not oviposit on bodies past the first 4–5 days. Calliphoridae flies may penetrate wrappings. There were no adult examples of Calliphoridae flies recovered from the sample.

- (2) Hymenoptera species do not penetrate wrappings to locate maggots and tend to look for exposed larvae. There were examples of adult Hymenoptera in the sample.
- (3) Tineidae are typical of later invading taxa.

We present one hypothetical scenario based upon the type of insects recovered from the individual (Figure 7). There is some flexibility inherent within the proposed timeline, given unknowns concerning specific environmental conditions and local insect populations.

The individual suffered cranial trauma, which was followed, presumably in fairly short order, by surgical intervention in the form of multiple trepanations (Aufderheide & Rodríguez-Martín, 1998; Zimmerman *et al.*, 1981). The individual survived for a short period of time, long enough for small areas of reactive bone to become apparent. It was during this time that the first wave of insects (Diptera) would have been attracted to necrotising flesh. Soft tissue wounds due to both the initial blunt trauma and the subsequent trepanations would have provided access points for insect colonisation. Perforation of the skull would also have provided access to the cranial cavity, allowing insects to colonise necrotising brain tissue. The open wounds may have led to soft

tissue infection, the result of which may still be evident in the grossly visible swelling of the left side of the face (Figure 8). This presumed infection may ultimately have been the cause of death. Hymenoptera species would have had to have access to the body in order parasitise mature Diptera larvae. In Belize and Hawaii, mature larvae can be found on a body during the decay stage, roughly three to eleven days after initial colonisation (Goff, 2001). As there were no recovered adult specimens of Calliphoridae, they either emerged prior to the wrapping of the individual, or managed to penetrate through the textiles. A single adult Diapriidae was recovered from the sample, which means that the textile wrappings were applied prior to its emergence from the pupa casing, trapping it within the mummy bundle.

Although limited, available data suggest that periosteal reactive bone appears sometime between 10 and 21 days following injury (Murphy *et al.*, 1990; Fechner & Mills, 1993: 11). This suggests, therefore, that death may have occurred sometime around Day 9 or 10 following injury. Furthermore, based upon the entomological evidence, initial insect colonisation may have begun prior to death. The presumed upper limit of 10 days for Hymenoptera activity, and the lower limit for the presence of periosteal reactive bone, coincide nicely. The evidence suggests that the individual was wrapped shortly after death. This is of course assuming that no artificial steps were taken to facilitate soft tissue preservation.

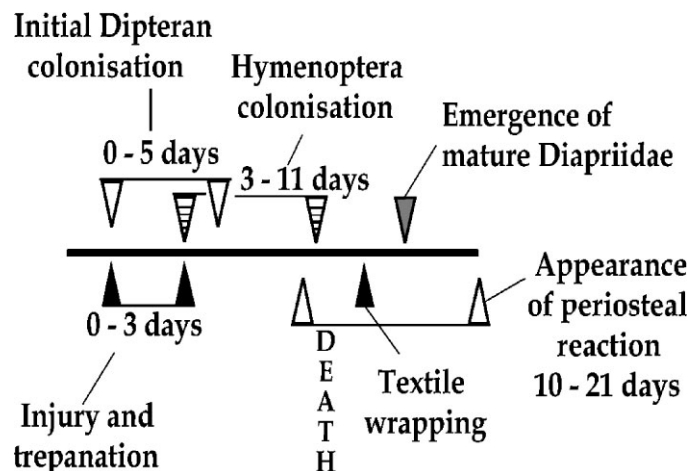


Figure 7. Hypothetical timeline of body processing based upon the type of insects recovered from the mummy bundle.



Figure 8. Grossly visible swelling of the left side of the face.

Alternatively, if artificial steps were taken to facilitate preservation, then we can allow for a longer period of time between death and wrapping. At the moment, however, there is no other evidence to suggest the presence of artificial mummification procedures.

Conclusions

Results were presented that allowed us to construct a hypothetical timeline concerning Chachapoya body processing. Following injury and resulting necrotising tissue, the individual was colonised by members of the Calliphoridae family. These insects will colonise a body almost immediately after death and up to four or five days after death. The maggots in turn became

parasitised by members of the Hymenoptera family. Examples of lateral emergence holes in puparial casings were present in the sample collected from the individual. An example of an adult wasp was recovered, which implies that it reached maturity after the individual was wrapped in textiles. The body had to be exposed in order for Hymenoptera to parasitise the puparial casings. This implies a range of time that could span anywhere from three to perhaps eleven days. The recovered remains of a member of the Tineidae family may be a much later artefact, perhaps acquired sometime during its storage in museums. Given the amount of soft tissue that remains, and the absence of definitive evidence for artificial preservation, the most parsimonious conclusion is that the individual was wrapped in textiles within 10 to 12 days of initial injury.

Dipteran colonisation probably occurred before death, followed closely by Hymenoptera.

Certain caveats must be articulated at this time concerning the data and the above discussion. First, and perhaps the most obvious, is that these results are derived from a single individual. Further, this individual may be unusual in that she died of unnatural causes. Mortuary treatment may differ significantly for those considered deviant in some way, and therefore the processing techniques may differ significantly from other individuals. We are not suggesting that these results should be taken as a gloss to be applied to mummification throughout the entire Chachapoya region. They should be taken as a case study that serves as a foundation for future research. Secondly, we have to consider the less than perfect preservation and context of the mummy bundle. Rather than a liability, however, we feel that in spite of the nature of the mummy, we have recovered significant data to further our understanding of mortuary behaviour in the Chachapoya region. This case study should illustrate the valuable nature of even the most damaged and disturbed contexts. Lastly, we should state that further refinement of these conclusions and future research will require experimental data derived from decomposition studies which account for differences in succession pattern due to environmental conditions and local insect species. In particular, we will have to establish the appearance and behaviour of parasitic wasps, which could alter the proposed timeline. In summary, the results presented in this paper have provided a unique glimpse into the mortuary behaviour of the Chachapoya. Beyond this, it is hoped that this case study will stimulate similar studies utilising other mummy collections, both old and new.

Acknowledgements

KCN would like to thank Andrew Nelson for his advice and help. He would also like to thank Melana Caceres Esquivel, director of the INC Departamento Amazonas, for providing access to the materials, and Rob Dover for his assistance. The authors would also like to thank three anonymous reviewers for their helpful comments and suggestions.

References

- Anderson GS, Van Laerhoven SL. 1996. Initial studies on insect succession on carrion in southwestern British Columbia. *Journal of Forensic Science* **41**: 617–625.
- Aufderheide AC, Rodríguez-Martín C. 1998. *The Cambridge Encyclopedia of Human Paleopathology*. Cambridge University Press: Cambridge.
- Avila FW, Goff ML. 1998. Arthropod succession patterns onto burnt carrion in two contrasting habitats in the Hawaiian Islands. *Journal of Forensic Science* **43**: 581–586.
- Bornemissza GF. 1957. An analysis of arthropod succession in carrion and the effect of decomposition on the soil fauna. *Australian Journal of Zoology* **5**: 1–12.
- Braack LEO. 1987. Community dynamics of carrion-attendant arthropods in tropical African woodland. *Oecologia (Berlin)* **72**: 402–409.
- Church WB, Morales GR. 2001. *Emergency Archaeology at the Tombs of Los Pinchudos, Perú*. Report to the National Geographic Society Committee for Exploration and Research.
- Coe M. 1978. The decomposition of elephant carcasses in the Tsavo (East) National Park, Kenya. *Journal of Arid Environments* **1**: 71–86.
- Cornaby BW. 1974. Carrion reduction by animals in tropical habitats. *Biotropica* **6**: 51–63.
- Early M, Goff ML. 1986. Arthropod succession patterns in exposed carrion on the island of O'ahu, Hawaiian Islands, USA. *Journal of Medical Entomology* **23**: 520–531.
- Faulkner DK. 1986. The mass burial: an entomological perspective. In *The Pacatnamu Papers*, Vol. 1, Donnan CB, Cook GA (eds). Museum of Cultural History, UCLA: Los Angeles; 145–150.
- Fechner RE, Mills SE. 1993. *Tumors of the Bones and Joints*. Armed Forces Institute of Pathology: Washington, DC.
- Gil N. 1936. Arqueología: Las Tumbas Esculturales de Aispachaka. *Sociedad Geográfica de Lima Boletín* **53**(4): 235–239.
- Goff AG. 2001. *Body Decomposition: An Influencing Factor in Ancient Maya Burial Practices*. Senior Honors Thesis, University of California, Los Angeles.
- Goff ML. 1993. Estimation of postmortem interval using arthropod development and successional patterns. *Forensic Science Review* **5**: 81–94.
- Guillén SE. 1998. Laguna de los Condores: Donde Viven los Muertos. *Bien Venida* **6**(24): 43–48.
- Hewadikaram KA, Goff ML. 1991. Effect of carcass size on rate of decomposition and arthropod succession patterns. *American Journal of Forensic Medicine and Pathology* **12**: 235–240.

- Jakobsen J, Jorgensen JB, Jorgensen LK, Schjellerup I. 1986–87. 'Cazadores de Cabezas' En Sitios Pre-Inca de Chachapoyas, Amazonas. *Revista del Museo Nacional* 48: 139–185.
- Jiron LF, Cartin VM. 1981. Insect succession in the decomposition of a mammal in Costa Rica. *New York Entomological Society* 89: 158–165.
- Kauffmann DF. 2002. *Historia y Arte del Perú Antiguo*, Vol. 4. PEISA: Lima, Perú.
- Kauffmann DF, Salazar M, Morales D, Mackay I, Sacay O. 1989. *Andes Amazonicos: Sitios intervenidos por la Expedición Antisuyo/86*. Arqueológicas 20. Museo Nacional de Antropología y Arqueología: Lima, Perú.
- Langlois L. 1934. Las Ruinas de Cuelap. *Boletín de la Sociedad Geographica de Lima* 51: 20–34.
- Langlois L. 1940a. Utcubamba: Investigaciones Arqueológicas en este valle del Departamento de Amazonas (Perú) Continuación. *Revista del Museo Nacional* 9(1): 33–72.
- Langlois L. 1940b. Utcubamba: Investigaciones Arqueológicas en este valle del Departamento de Amazonas (Perú) Conclusión. *Revista del Museo Nacional* 9(2): 191–225.
- Morales GR, Alvarez LV, Church WB, Tello LC. 2002. Los Pinchudos: Un estudio preliminar de su población. *Sian* 8(12): 1–41.
- Murphy SP, Sledzik PS, Mann RW, Kelley MA. 1990. *Bone Remodeling Following Trauma: Reconsidering the Term Perimortem*. Paper presented at the 42nd Annual Meeting of the American Academy of Forensic Sciences, Cincinnati, Ohio.
- Muscutt K. 1998. *Warriors of the Clouds: A Lost Civilization in the Upper Amazon of Perú*. University of New Mexico Press: Albuquerque.
- Muscutt K. 2003. *History Channel Site Report on Vira Vira, Perú*. Report in the possession of the author, Department of Anthropology, University of New Mexico, Albuquerque, NM 87131.
- Nelson AJ. 1998. Wandering bones: archaeology, forensic science and Moche burial practices. *International Journal of Osteoarchaeology* 8: 192–212.
- Nystrom KC. 2003. *Report on the Human Remains Recovered from the Laguna Huayabamba, Chachapoyas, Perú*. Report in the possession of the author, Department of Anthropology, University of New Mexico, Albuquerque, NM 87131.
- Payne JA. 1965. A summer study of the baby pig *Sus scrofa linnaeus*. *Ecology* 46: 592–602.
- Reed HB. 1958. A study of dog carcass communities in Tennessee with special reference to the insects. *American Midland Naturalist* 59: 213–245.
- Richards EN, Goff ML. 1997. Arthropod succession on exposed carrion in three contrasting tropical habitats on Hawaii Island, Hawaii. *Journal of Medical Entomology* 34: 328–339.
- Rodriguez WC, Bass WM. 1983. Insect activity and its relationship to decay rates of human cadavers in eastern Tennessee. *Journal of Forensic Science* 28: 423–432.
- Schjellerup I. 1997. *Incas and Spaniards in the Conquest of the Chachapoyas, Archaeological and Ethnohistorical Research in the North-eastern Andes of Peru*. GOTARC, series B, Gothenburg Archaeological Theses 7: Göteborg University.
- Schjellerup I, Sørensen MK, Espinoza C, Quipuscoa V, Peña V. 2003. *The Forgotten Valleys: Past and Present in the Utilization of Resources in the Ceja de Selva, Perú*. Ethnographic Monographs No. 1. The National Museum of Denmark: Copenhagen.
- Shalaby OA, deCarvalho LML, Goff ML. 2000. Comparisons of patterns of decomposition in a hanging carcass and a carcass in contact with soil in a xerophytic habitat on the island of Oahu, Hawaii. *Journal of Forensic Science* 45: 1231–1237.
- Tullis K, Goff ML. 1987. Arthropod succession in exposed carrion in a tropical rainforest on O'ahu Island, Hawai'i. *Journal of Medical Entomology* 24: 332–339.
- von Hagen A. 2002. Chachapoya iconography and society at Laguna de los Cóndores, Perú. In *Andean Archaeology Volume II: Art, Landscape, and Society*, Silverman H, Isbell WH (eds). Kluwer Academic/Plenum Publishers: New York; 137–155.
- Zimmerman MR, Trinkaus E, Lemay M, Aufderheide AC, Reyman TA, Marrocco GR, Shultes RE, Coughlin EA. 1981. Trauma and trephination in a Peruvian mummy. *American Journal of Physical Anthropology* 55: 497–501.